ISAKOS CONGRESS 2025 | MUNICH GERMANY June 8–11

MODIFIED JUDET QUADRICEPSPLASTY LEADS TO ENHANCED KNEE FUNCTION IN PATIENTS WITH POST-TRAUMATIC KNEE STIFFNESS: A CASE SERIES OF 19 CONSECUTIVE PATIENTS

Giulio Maria Marcheggiani Muccioli, MD, PhD, Associate Professor, Bologna (Italy)
Vito Gaetano Rinaldi, MD, Bologna (Italy)
Domenico Alesi, MD, Bologna (Italy)
Alberto Fogacci, MD, Bologna (Italy)
Matteo La Verde, MD, Bologna (Italy)
Iacopo Sassoli, MD, Bologna (Italy)
Alberto Grassi, MD, Bologna (Italy)
Stefano Zaffagnini, MD, Professor, Bologna (Italy)

FACULTY DISCLOSURE INFORMATION

- Giulio Maria Marcheggiani Muccioli: LINK
- Stefano Zaffagnini: Smith&Nephew, Depuy

POST-TRAUMATIC KNEE EXTENSION CONTRACTURE

DEFINITION

The definition of knee stiffness remains controversial. A variety of criteria are used to diagnose knee stiffness: flexion contracture >15° and/or <75° flexion; >10° extension deficit and/or <95° flexion; total knee range of motion <70°

CAUSES

Trauma
Infiammatory/infective joint disease
After cast immobilization
Scarred skin
Post-surgery
Delayed physiotherapy

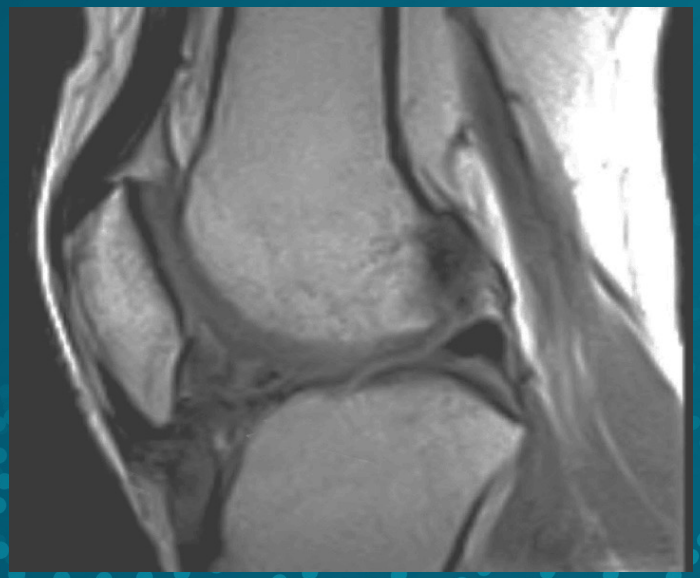

INCIDENCE

(per surgery type)

ACL, Arthroscopic procedures: 2-35%
Multi-ligament: 13-24%
TKA: 1-12%
ORIF Tibial fracture: 14-15%
Femoral fracture: 29-30%

STIFFNESS COMPONENTS

Intrarticular
Extrarticular

RISK FACTORS

Patient

- Genetic predisposition
- Previous surgery
- Poor pain tollerance

Post-operative

- Not aggressive/delayed FKT
- Lack of patient motivation
- Prolunged immobilization
- Lack of activity

Surgery

- Timing
- Fracture malreduction
- External fixation
- Complex and invasive

Trauma / Healing

- Fracture severity
- Large soft tissue injury
- Hypertrofic callus

TREATMENT STRATEGY

! If there is no improvement by three months post op, the next steps are surgical.

JUDET QUADRICEPSPLASTY

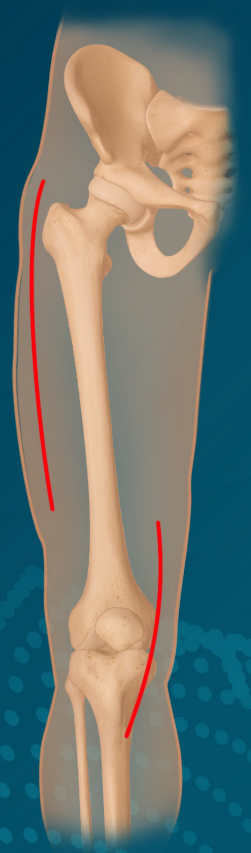

An alternative technique (Robert and Jean Judet, 1956):

- Medial approach (Gernez) for artholysis
- Lateral cut: until great trocanter
- Adhesions release between anatomical layers
- Vastus lateralis release; vastus intermedius lifted off anterlolateral femur extra-periosteum
- Detaching vastus lateralis at great trochanter origin + section rectus femoris tendon below its division
- Severe cases of stiffness only the skin is sutured

Sequential release reduces potential risks for extensor apparatus and dissection extension

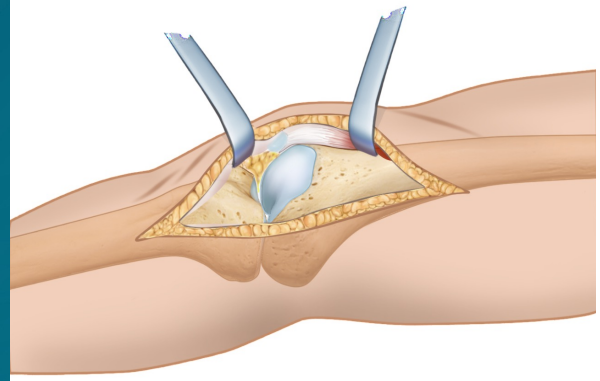

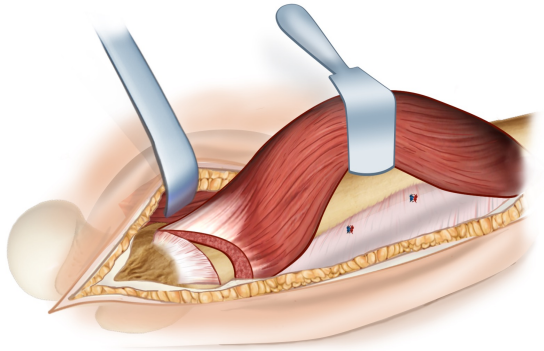

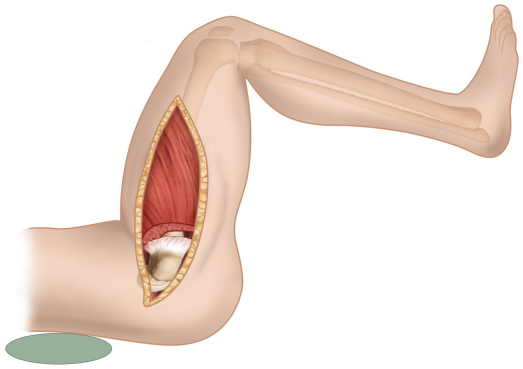

MODIFIED JUDET: OUR TECHNIQUE

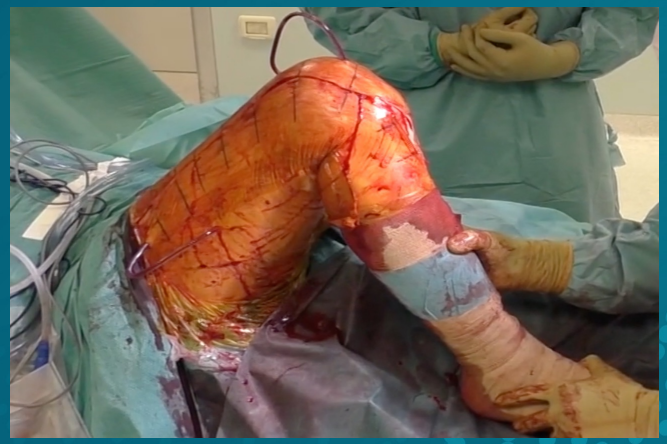

Lateral approach: from 5 cm below greater trochanter to Gerdy tubercle

Adhesions release between anatomical layers

Lateral patellar retinaculum release, remove scar tissues in the suprapatellar gutter and patello-femoral joint

Progressive detachment of the vastus lateralis until greater trochanter without disconnecting it from its origin

Vastus intermedius lifted off anterolateral femur surface extraperiosteally

Carry out cautious manipulations

TIPS AND TRICKS

Mark with **dermographic pen** the surgical access on the fascia lata in line with the skin access then draw vertical references

Identification **locus minoris resistentiae** at the distal portion of the vastus lateralis and **perforating** vessels that penetrate from septum into the muscle

Synthesis devices **removal** after forced knee flexion attempts

Final flexion after release: at least **110°-120°**

Final suture with **knee flexion > 90°**

Suture the fascia lata shifting two flaps (Z-plastic)
Do **not suture** the lateral patellar retinaculum
Suture distal fascia on the tibia without shifting

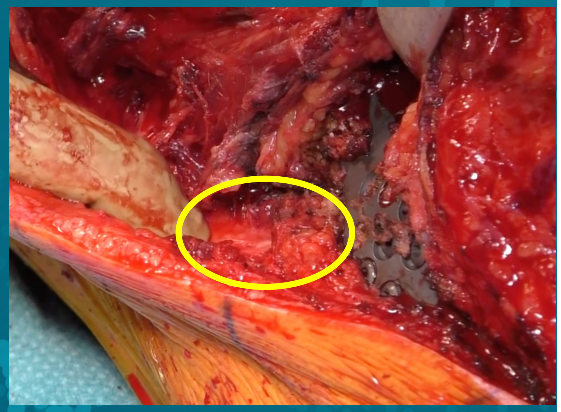

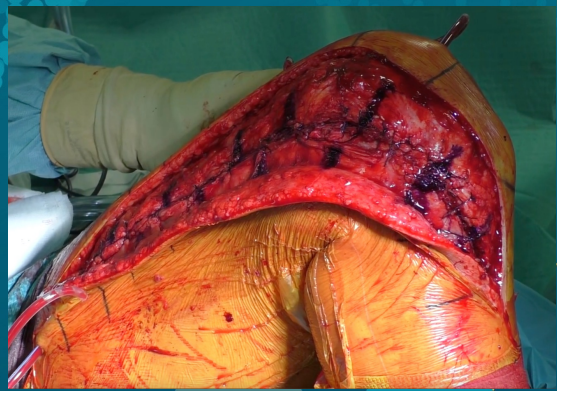

MODIFIED JUDET QUADRICEPSPLASTY: RIZZOLI ORTHOPEDIC INSTITURE STUDY

Study length: **February 2024 - May 2024**

Mean follow-up: **10.16 years (range 1-16)**

Retrospective and prospective observational study

Single center

General patients' characteristics	
Gender	17 Male (89.5%) 2 Female (10.5%)
Mean age at surgery	34.5 years (19-46; SD ±6.79)
BMI	26.03 kg/m^2 (20.1-44.7; SD ±5.43)
Side of surgery	9 Left (47.4%) 10 Right (52.6%)
Comorbidities	None

PATIENTS CLINICAL HISTORY

INJURY

Extra-articular distal femoral fracture 11 (57.9%)

Tibial plateau fracture 1 (5.3%)

Intra-articular distal femur fracture + patella fracture 2 (10.5%)

Intra-articular distal femur fracture + tibial plateau fracture 3 (15.7%)

III° mid femoral diaphysis fracture 1 (5.3%)

Meniscal injury 1 (5.3%)

Fractures with exposure 9 (47.4%)

TREATMENT

ORIF 19 (79.2%)

External fixation 4 (16.7%)

Meniscectomy 1 (4.1%)

AVERAGE TIME INJURY-ARTROMIOLYSIS

34 months (range 5-199), DS ± 42.80

PREVIOUS SURGERY

I° surgery Judet 11

Mua/artromiolisis/artrolisis 8

CLINICAL OUTCOME

Case	**Pre-op flexion (°)**	Pre-op lack extension (°)	**Intra-op flexion (°)**	Intra-op lack extension (°)	Pre/intra-op flexion gain (°)	**Flexion at 1 month (°)**	Lack extension at 1 month (°)	**Last FU flexion (°)**	**Flexion gain** pre-op/last FU (°)	**Gain-loss** flexion intra-op/last FU (°)	Lack extension last FU (°)
1	90	0	135	0	45	120	0	133	43	- 2	10
2	65	0	135	0	70	135	0	140	75	+ 5	0
3	10	0	135	0	125	100	0	80	70	- 55	8
4	80	0	120	0	40	100	0	130	50	+10	0
5	50	0	120	0	70	85	0	85	35	- 35	2
6	40	0	90	0	50	50	0	55	15	-35	0
7	20	0	110	0	90	30	5	113	93	+3	10
8	70	0	110	0	40	110	0	110	40	0	5
9	20	0	110	0	90	30	0	115	95	+5	0
10	60	0	90	0	30	90	0	90	30	0	0
11	30	0	90	0	60	60	0	80	50	-10	7
12	70	0	120	0	50	110	0	93	23	-27	12
13	85	0	135	0	50	100	0	110	25	- 25	0
14	40	0	90	0	50	60	0	87	47	- 3	0
15	45	5	120	5	75	90	0	120	75	0	0
16	80	20	110	0	30	110	0	130	50	+ 20	6
17	30	5	120	0	90	90	10	35	5	- 85	20
18	0	0	90	0	90	100	0	100	100	+ 10	0
19	70	0	120	0	50	100	0	107	37	- 13	0
AVERAGE	**50.26**		**113.16**		**62.89**	**87.89**		**100.68**	**50.42**	**-12.48**	

CLINICAL SCORE

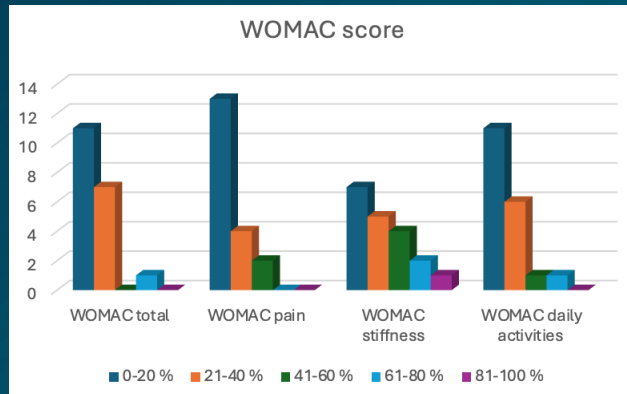

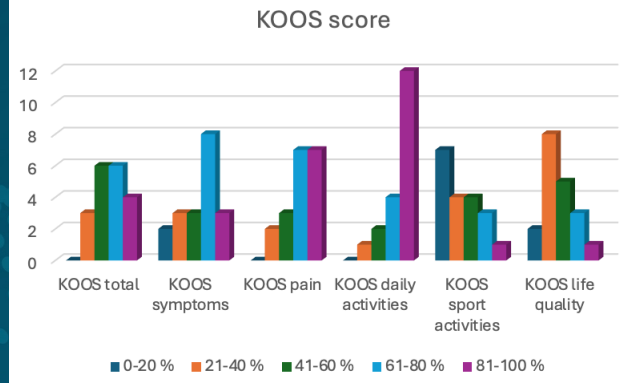

VERY GOOD CLINICAL RESULTS AT LAST FU

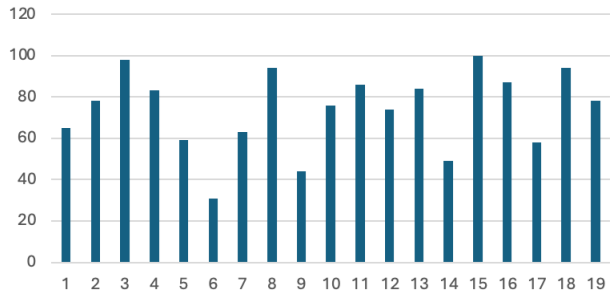

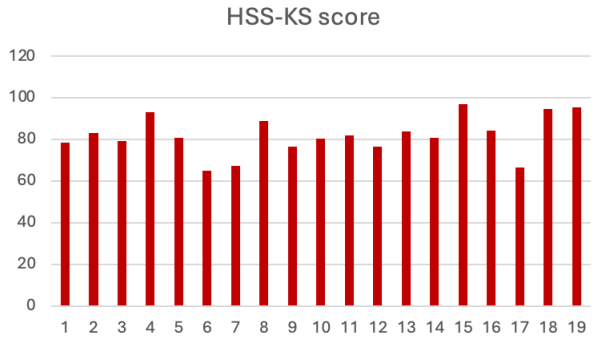

CONCLUSION

ACCORDING TO JUDET'S CRITERIA

Excellent **10**
Good **7**
Fair **1**
Poor **1**

COMPLICATIONS

Intra-operative: 1 patellar tendon detachment
Post-operative: 1 osteomyelitis, 2 infections, 1 hematoma, 1 bleeding

FAILURE

4 cases needed a new arthromiolysis after modified Judet quadricepsplasty

TAKE HOME MESSAGES

Modified Judet quadricepsplasty: effective for post-traumatic knee stiffness
Performed by experienced surgeons and followed by active + passive fkt
Results maintained over the long term

References
Cheuy V.A. et al. *Arthrofibrosis Associated With Total Knee Arthroplasty*, The Journal of Arthroplasty, 2017 Feb
Vaish A. et al *Etiopathology and Management of Stiff Knees: A Current Concept Review*, Indian Journal of Orthopaedics, 2020 Oct
Usher K.M. et al *Pathological mechanisms and therapeutic outlooks for arthrofibrosis*, Bone Research, 2019 Mar
Pujol N. et al *Post-traumatic knee stiffness: surgical techniques*, Orthop Traumatol Surg Res, 2015 Feb
Oliveira VG et al. *Judet quadricepsplasty in the treatment of posttraumatic knee rigidity: Long-term outcomes of 45 cases*, J Trauma Acute Care Surg. 2012 Feb